

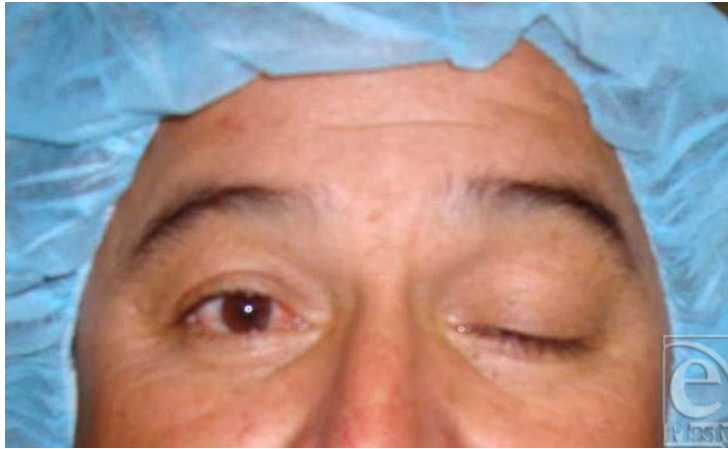
Interesting Case Series

Congenital Blepharoptosis

Rohit Jaiswal, BA, and Nabil Habash, MD

Department of Surgery, Division of Plastic Surgery, The Ohio State University
Medical Center, Columbus, Ohio

Correspondence: Rohit.Jaiswal@osumc.edu



DESCRIPTION

A 40-year-old man with congenital blepharoptosis underwent a mild correction procedure at 10 years of age. Approximately 10 years ago, he felt a “pop” and since has had complete recurrence of ptosis in the left eye.

NEXT

QUESTIONS

- 1. What are important anatomical structures associated with elevation of the upper eyelid?**
- 2. What are the common causes of blepharoptosis?**
- 3. Which surgical procedures are available to correct this condition?**

[BACK](#)

[NEXT](#)

DISCUSSION

Upper eyelid movement involves 3 muscles: the levator palpebrae superioris, the superior tarsal muscle (Muller's muscle), and the frontalis. The levator palpebrae, innervated by cranial nerve III, functions to elevate the eyelid by 10 to 12 mm. Muller's muscle, innervated by sympathetics, elevates the eyelid an additional 2 to 3 mm. The frontalis is controlled by cranial nerve VII and elevates the brow and upper eyelid skin. The levator palpebrae superioris originates on the lesser wing of the sphenoid, broadens into the levator aponeurosis, and inserts onto the tarsal plate and dermis of the upper eyelid skin. Muller's muscle originates on the posterior portion of the levator palpebrae and inserts onto the superior tarsal plate. The frontalis originates in the galea aponeurosis and inserts into the suprabrow dermis.

Blepharoptosis (or ptosis) is the abnormally low position of the upper eyelid and may be congenital or acquired. Congenital ptosis is usually myogenic in nature, with the levator muscle diminished or absent and replaced with fibrous and adipose tissue. Acquired ptosis is more diverse in etiology. Most common is aponeurotic ptosis in which the levator aponeurosis may dehisce or disinsert from the anterior portion of the tarsal plate as one ages. Similarly, traumatic ptosis presents the same anatomic pathology after some inciting event, commonly cataract surgery or deep eyelid laceration. Neurogenic ptosis usually results from cranial nerve III palsy, Horner's syndrome, or myasthenia gravis. Mechanical ptosis results from physical obstruction to upper lid elevation, such as eyelid neoplasms or postinflammatory scarring.

The procedure of choice is often dependent on the severity of ptosis and degree of levator function. Generally, mild ptosis (2–3 mm) is associated with good levator function (10–15 mm), moderate ptosis (3–5 mm) with fair levator function (6–9 mm), and severe ptosis (>5 mm) with poor levator function (<5 mm). If levator function is classified as good or fair, corrective procedures may include tarsal-conjunctival mullerectomy, levator plication, or levator advancement. In patients with poor levator function, the frontalis suspension (or sling) procedure with the tensor fascia lata may be used (Figs 1–5).

[BACK](#)

[NEXT](#)

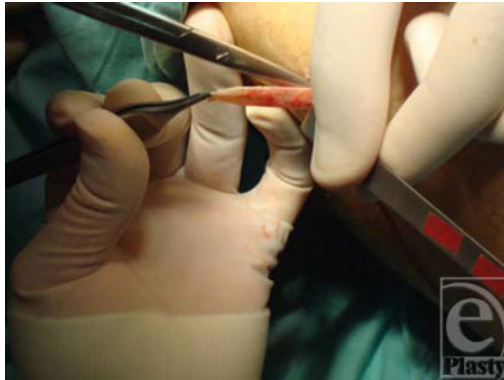


Figure 1. Tensor fascia lata being harvested.

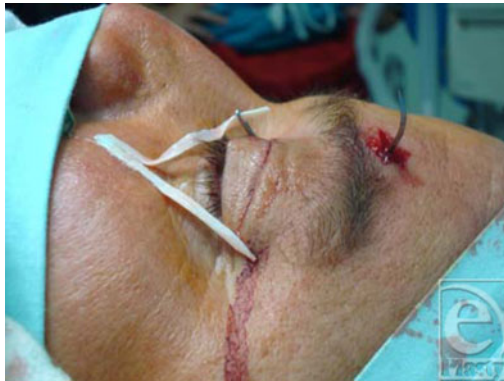

Figure 2. Tensor fascia lata is to be tunneled via needle.

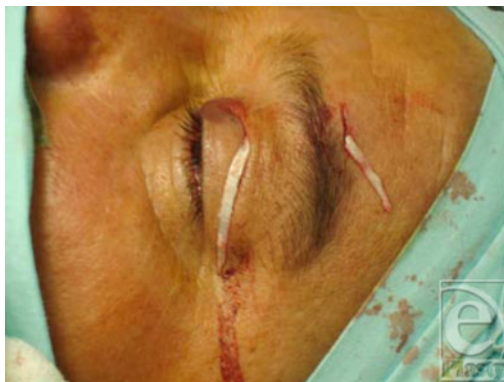

Figure 3. Tensor fascia lata tunneled, ready to be tethered.

BACK

NEXT

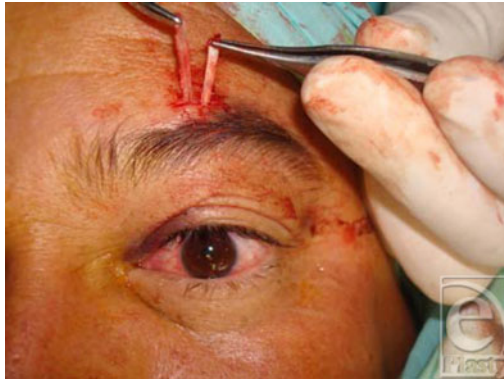

Figure 4. Simulation of suspension via tensor fascia lata.

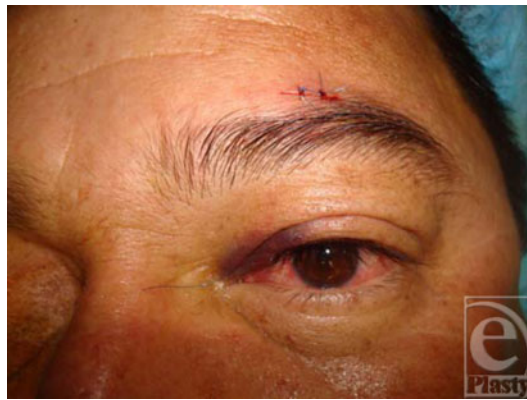

Figure 5. Postoperative depiction of suspension of the upper eyelid.

Suggested Readings

1. Newman MI, Spinelli HM. Reconstruction of the eyelids, correction of ptosis, and canthoplasty. In: Thorne CH, ed. *Grabb and Smith's Plastic Surgery*. 6th ed. Philadelphia, Pa: Lippincott Williams & Wilkins; 2006:397-417.
2. Cohen AJ, Mercandetti M. Ptosis, adult. *eMedicine*. 2009. Available at: <http://emedicine.medscape.com/article/1212082-overview>. Accessed November 26, 2009.
3. Bashour M. Blepharoplasty, ptosis surgery. *eMedicine*. 2009. Available at: <http://emedicine.medscape.com/article/839075-overview>. Accessed November 27, 2009.

Rohit Jaiswal. Congenital Blepharoptosis. www.ePlasty.com, Interesting Case, February 25, 2010

BACK